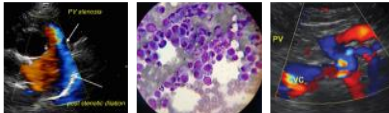


IMAGING PERFORMED BY

IntraPet.com



PATIENT

Barbie Q Sublett

SPECIES

Feline

BREED

DSH

SEX

Female Spayed

AGE

10.18.08

WEIGHT

7.8lbs

INTERPRETED BY

Maggie Machen Lamy,
DVM, DACVIM
(Cardiology)

HOSPITAL NAME

Charm City Veterinary
Hospital

REFERRING VET

Dr. Hansen

INVOICE

27975

DATE

12.13.22

PRESENTING CLINICAL SIGNS

History: Intermittent premature beats with pulse deficits. Grade 1-2/6 left systolic murmur. Brown to green mucoid ocular/nasal discharge. Generalized muscle atrophy. Bladder empty- blood clots near vulva yest. Weight loss.

- Abnormal lab results: Unremarkable CBC/CHEM/T4
- Current medications: Ondansetron 1-2 mg PO q12h, Doxycycline 10 mg/kg q24, Mirtazipine TD
- Sedation used: Patient sedated with Torbugesic.
- Pertinent previous ultrasound results: No previous.
- STAT: Not requested
- Imaging performed by: Andi Parkinson, BS, RDMS.

ECHOCARDIOGRAM FINDINGS

2D, m-mode, color flow and doppler imaging is available. The left ventricular wall is normal in dimension with regions of thinning and irregularity. There is a diffusely hyperechoic endocardium consistent with fibrosis. The papillary muscles are mildly remodeled and hyperechoic. The endocardium also appears remodeled. The left atrium is normal in size. The right atrium is normal in size. The right ventricle appears normal. The mitral valve is normal in structure and mobility. No TR. Blood flow through both the LVOT and RVOT is normal in velocity. Trace AI. No pleural or pericardial effusion seen. No obvious cardiac tumors.

CARDIAC CHART

| FELINE CARDIAC PARAMETERS | BODY WEIGHT (kg) | HR (BPM) | IVSd (cm) <small>(Moise, Pipers)</small> | LVIDd (cm) <small>(Moise, Pipers)</small> | LWVd (cm) <small>(Moise, Pipers)</small> | FS (%) | EF (%) |
|---------------------------|---------------------|------------------------------------|--|---|--|----------------|-----------|
| NORMAL PARAMETER | ----- | 150-240 | 3.5-0.55 | <2 (mean 1.5) | 3.5-0.55 | 35-67 | 80-100 |
| PATIENT | 3.5 | 165 | 0.55 | 1.0 | 0.53 | 43 | 79 |
| FELINE CARDIAC PARAMETERS | LA/AO (Boon) | LA/AO HEART BASE (Swe) (Abbott) | LA 2D short axis Base view (cm) (Abbott) | LVOT VEL (m/s) | RVOT VEL (m/s) | E max (m/s) | |
| NORMAL | <1.5 | <1.3 | <1.2 | <1.6 | <1.3 | <0.9 | |
| PATIENT | NM | 1.2 | 1.0 | 0.92 | 0.7 | NM | |

Adapted from June Boon, Veterinary Echocardiography, 1998
Abbott J & MacLean H JVIM 2006;20: 111-119, Moise et al. Am J Vet Res 47:1476, 1986. Pipers et al. Am J Vet Res 40:882, 1979.

INTERPRETATION OF THE FINDINGS & FURTHER RECOMMENDATIONS

Overtly normal geriatric cardiac dimensions and function. No LV hypertrophy or chamber dilation is identified. The LA is normal indicating low risk for complication. A small aortic insufficiency is appreciated, and a baseline BP recommended. No additional issues are identified.

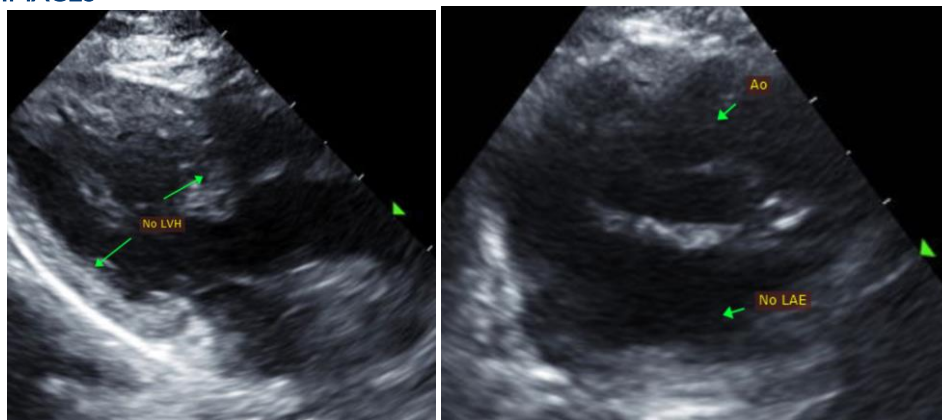
No cardiac cause for an arrhythmia is seen in this study. Systemic/extra-cardiac causes should be considered in a senior cat. Full systemic evaluation is advised including abdominal ultrasound as indicated. Follow up/treatment for the arrhythmia should be dictated based upon the ECG report/evaluation.

No cardiac contraindication for general anesthesia from a structural standpoint. This does not address the arrhythmia which again should be dictated by the ECG report.

Monitor for any development of clinical signs at home, including labored breathing, cough or signs of a blood clot (paralysis, neurologic change). No cardiac medications are clearly indicated.

A recheck echocardiogram is recommended in 12 months to screen for development of silent disease, sooner if a murmur, gallop or any respiratory signs are identified.

IMAGES



The information and recommendations provided are based on the images presented by the referring veterinarian. No evaluation can be communicated regarding pathology that was not visible in the image/video clips provided.

Thank you for this referral. This report was generated using transcription software, and minor dictation errors may be present. If the clinical or image interpretation does not parallel your findings or if I can be of any further assistance please contact me.

Maggie Machen Lamy, DVM
Diplomate of the American College of Veterinary Internal Medicine (Cardiology)
info@sonopath.com